

# Elekta Axesse™ Case Study

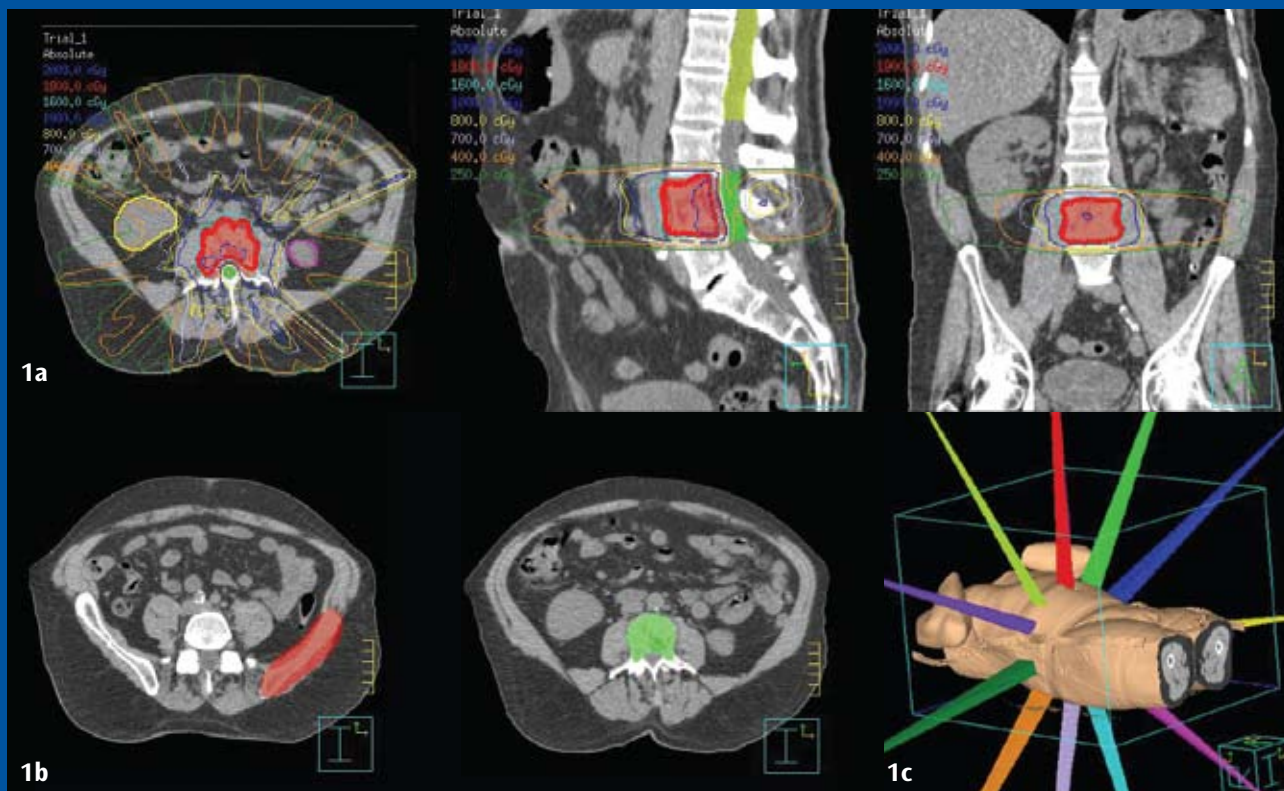


Figure 1. 1a: Dose distribution of the 11-field image-guided radiosurgery plan with conformal limits to cord, thecal sac and kidneys. 1b: The targets. 1c: Beam arrangement.

## Image Guided Radiosurgery of Spinal Tumors and Metastases

<b>Institution:</b>	William Beaumont Hospital, Detroit, MI
<b>Radiation Oncologists:</b>	James Fontanesi, MD
<b>Medical Physicists:</b>	Tiezhi Zhang, PhD, Jennifer L. Wloch, Di Yan, DSc
<b>Patient:</b>	67-year-old male
<b>Diagnosis:</b>	Adenocarcinoma of the lung Metastases to the lumbar spine and iliac crest
<b>Plan:</b>	11-field, coplanar, unopposed beam arrangements
<b>Treatment:</b>	Target – 18Gy single fraction
<b>Treatment System:</b>	Elekta Axesse™

Elekta Axesse™ is a stereotactic treatment solution providing head-to-toe, three-dimensional, image-guided stereotactic radiosurgery and radiotherapy. Fully optimized for neurosurgery, Elekta Axesse is ideally suited for stereotactic radiosurgery of the spine and body, providing total treatment control with proven technology and no compromise in productivity.

# Stereotactic Radiosurgery of Spinal Metastases using Elekta Axesse™

## Patient diagnosis and history

In July 2006, a patient presented with increasing cough and shortness of breath. In August, the patient had a bronchoscopy and was diagnosed with moderately differentiated adenocarcinoma of the lung. He underwent chemotherapy consisting of Gemzar® and Carboplatin, and was doing well until January 2008 when a routine follow-up bone scan revealed increased activity at L4. Questionable activity was also noted in the left iliac crest. A PET scan was positive in both regions. Based on the clinical exam, the patient was an excellent candidate for single-fraction stereotactic radiation treatment to the lumbar spine, as well as the superior aspect of the left iliac crest.

## Planned treatment

An optimized 11-field, coplanar unopposed beam arrangement using 6-MV photons was designed using Pinnacle3® (Figure 1c). The isocenter was set in the center of the target at L4. The prescription dose was 18Gy administered in a single fraction to the planning target volume. The maximal dose to the thecal sac was 9.9Gy and the maximal dose to both kidneys was 7.9Gy. About 95% of the target volume received at least 18Gy and the maximal target dose was approximately 22Gy. The left iliac crest was also treated with two oblique beams to a total dose of 6Gy, using the same isocenter.

The patient was immobilized using the Elekta Axesse spine fixation BodyFIX® system, and a planning CT scan acquired for use in treatment planning. Prior to treatment, three-dimensional cone-beam CT (CBCT) images were acquired on the treatment set, then registered on-line with the planning CT scan to determine a full six-degree position correction. The patient's position was then corrected using the Elekta Axesse 6D automatic patient positioning system. The attending physician verified the treatment setup using a post-correction CBCT and orthogonal portal images.

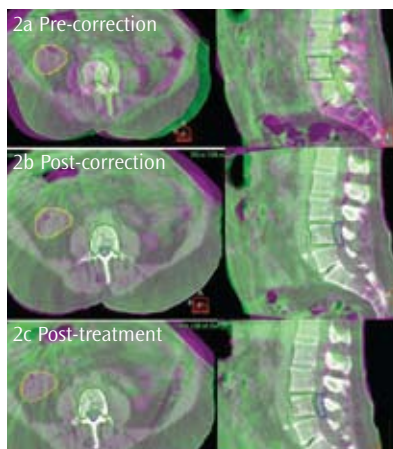


Figure 2. Transverse and sagittal views. VoumeView™ images (Pink = planning CT image, Green = CBCT image) show uncorrected (2a) and corrected (2b) positions. Post-treatment images (2c) were also acquired to exam patient's movement during the treatment course.

The patient tolerated the treatment well and completed the treatment course without any delays. After treatment, a third CBCT image set re-confirmed the patient's setup.

## Outcome and follow-up

The patient was pain free at his one-month follow-up with an associated reduction in narcotic requirements.

## Discussion

Stereotactic radiosurgery of spine metastases was optimized with on-line position corrections using Elekta Axesse. High precision localization and position correction ensured accurate dose delivery to the tumor and minimized unnecessary exposure of the critical and normal tissues. The field-size on the Elekta Axesse high-resolution multileaf collimator was large enough to treat two targets approximately 10 cm apart in a single treatment, thereby avoiding the need for re-imaging and setup. Total treatment time was approximately 45 minutes.

# Beaumont®

## Total Treatment Time

**45 Minutes**

Patient Setup	5 Min
Pre-CBCT	5 Min (2 scan/3 register)
Patient Re-alignment	2 Min
Verification CBCT	3 Min (2 scan/1 verify)
Verification MV Images	3 Min
Time	25 Min
Post CBCT	2 Min

"Elekta Axesse™ has proven to be a fully integrated stereotactic radiosurgery system. Its precise treatment delivery gives us a high level of confidence when using a single fraction, or hypofractionated protocols."

Tiezhi Zhang, PhD  
Physicist  
William Beaumont Hospital



Note: Approval of indications may vary between different countries, additional regulatory clearances on some markets may be required. Not intended for Japan and USA.

www.elekta.com

Human Care Makes the Future Possible

### Corporate Head Office:

Elekta AB (publ)  
Box 7593, SE-103 93 Stockholm, Sweden  
Tel +46 8 587 254 00  
Fax +46 8 587 255 00  
info@elekta.com

### Regional Sales, Marketing and Service:

North America  
Atlanta, USA  
Tel +1 770 300 9725  
Fax +1 770 448 6338  
info.america@elekta.com

Europe, Latin America,  
Africa, Middle East & India  
Tel +44 1293 544 422  
Fax +44 1293 654 321  
info.europe@elekta.com

Asia Pacific  
Hong Kong, China  
Tel +852 2891 2208  
Fax +852 2575 7133  
info.asia@elekta.com

